

56 yo F with RUQ pain and
jaundice

PHILIPS

09/09/2011

15:59:09

TIS0.6 MI 1.2

AM00743807

Rose Medical Center

C5-1/Abd Gen

ABDOMEN US COMPLETE

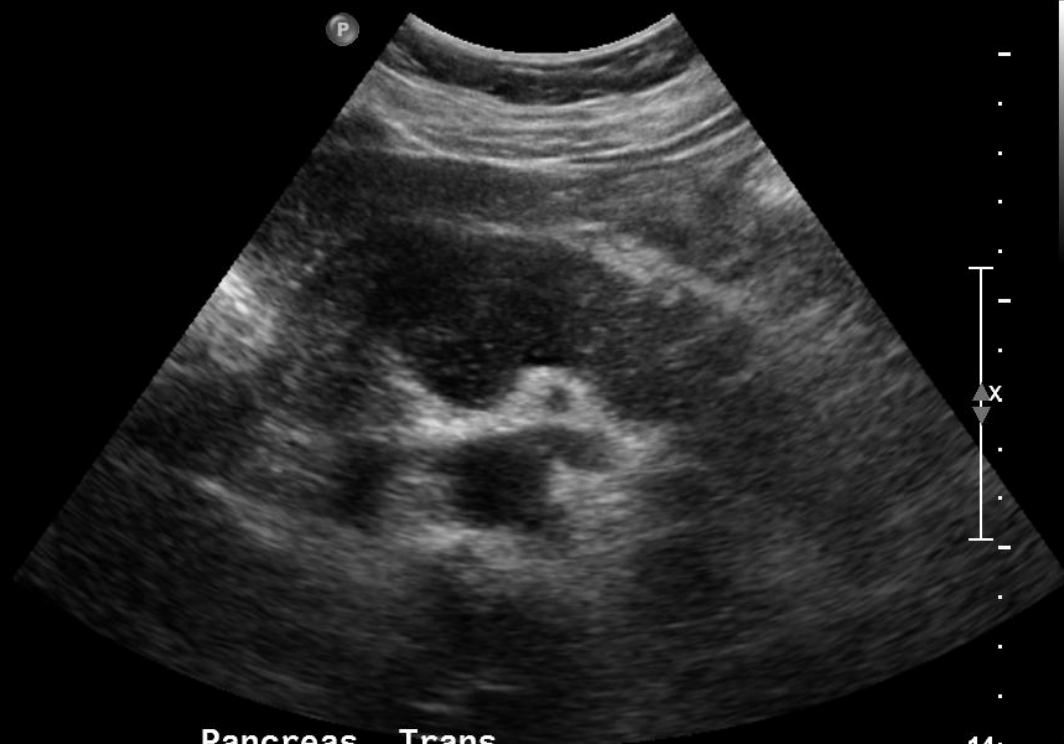ABDOMEN US COMPLETE

9/9/2011 3:59:11 PM

00125559

56 YEAR
F
FR 28Hz
RS

2D
39%
C 55
P Low
Gen



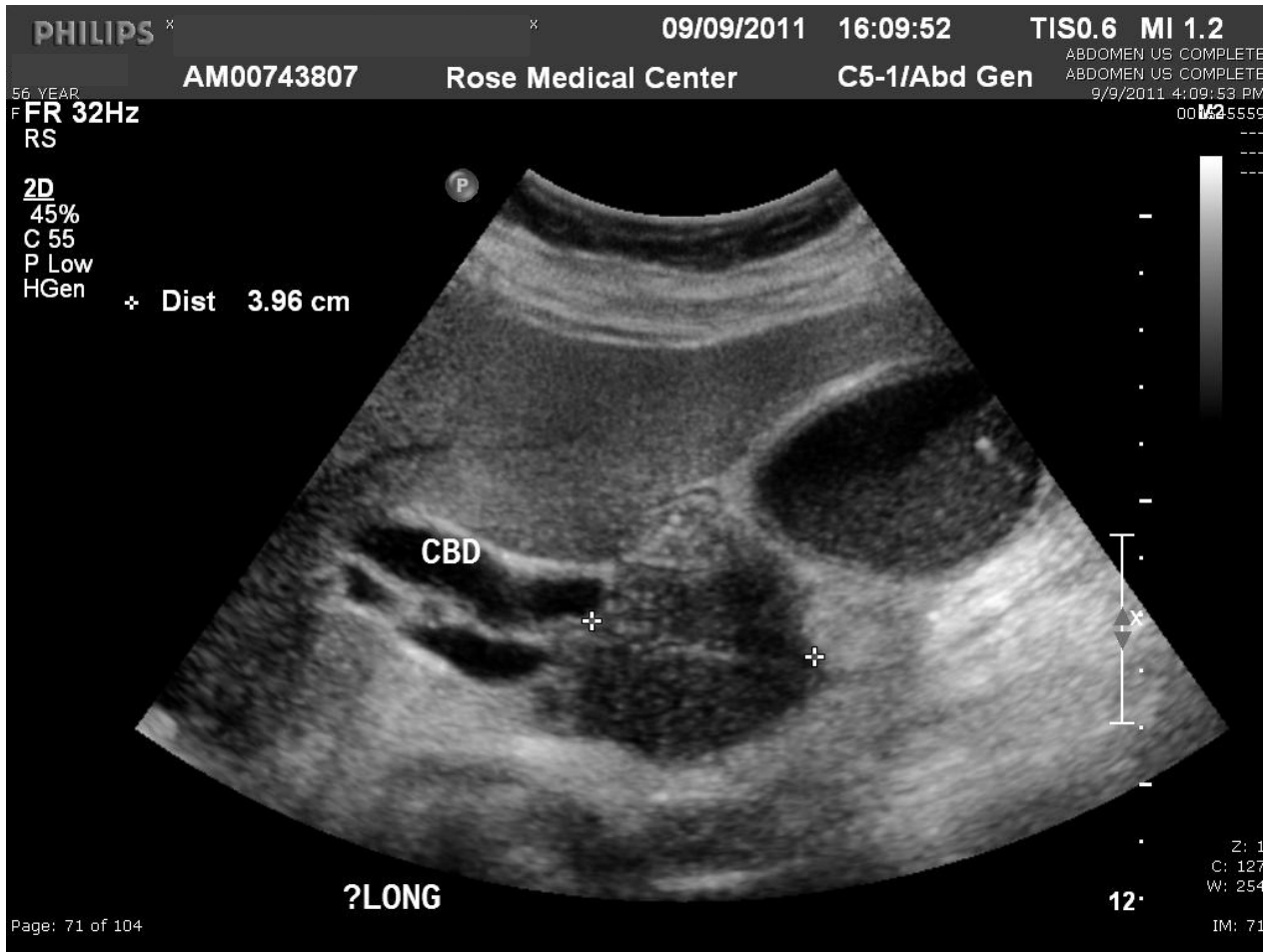Pancreas Trans

14

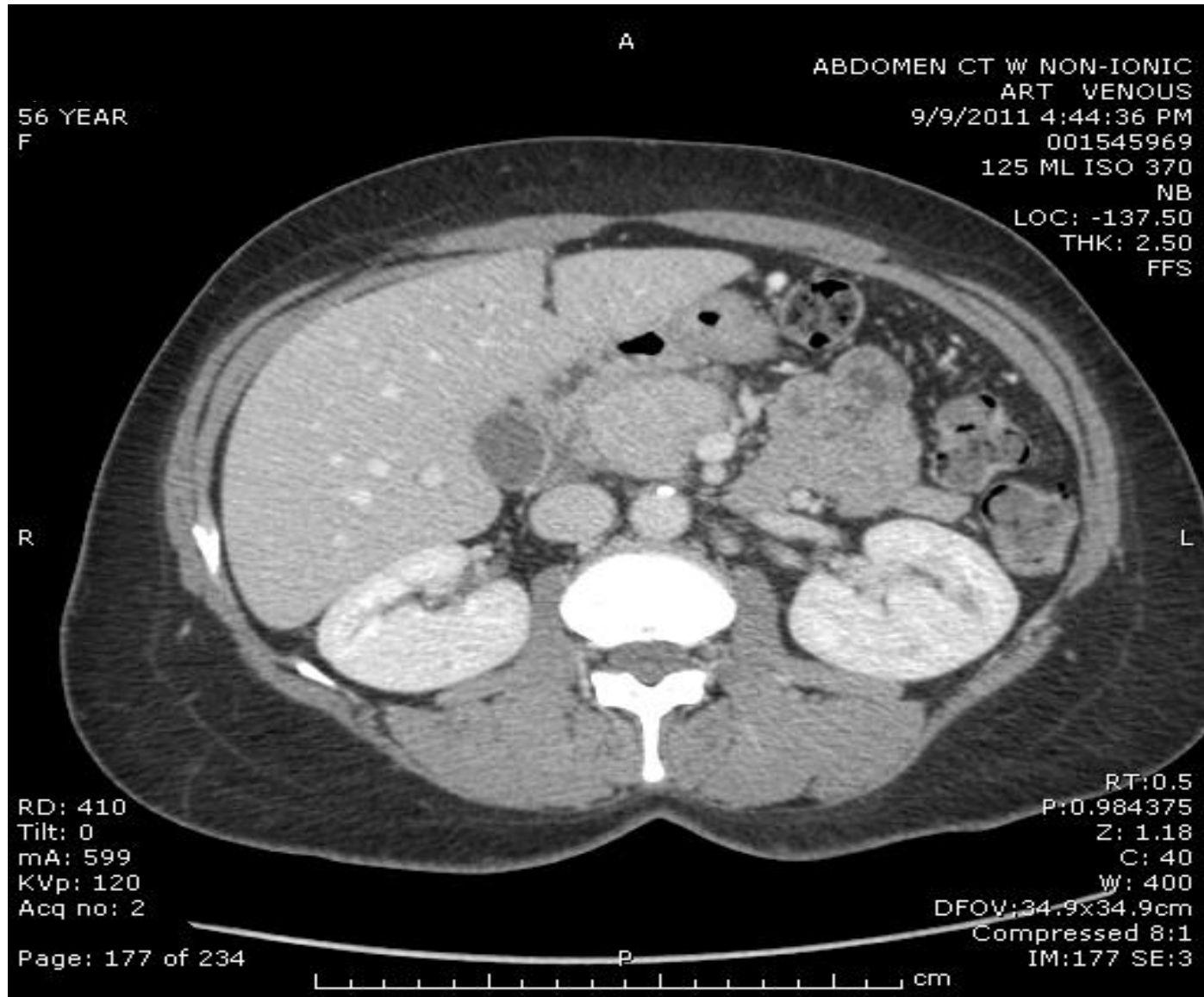
Z: 1
C: 127
W: 254

IM: 4

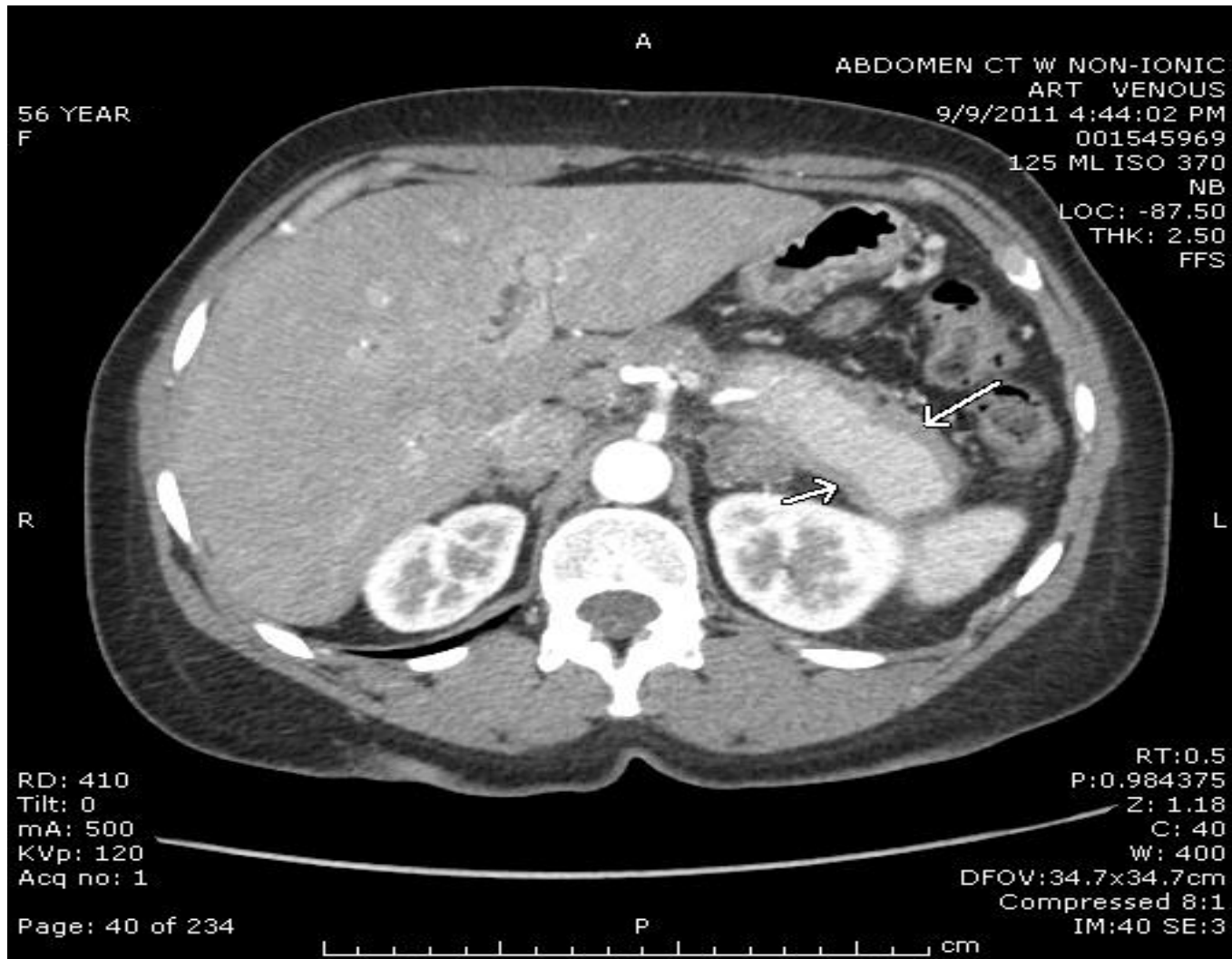US – presumed panc head mass, dilated thickwalled CBD terminates in “mass”



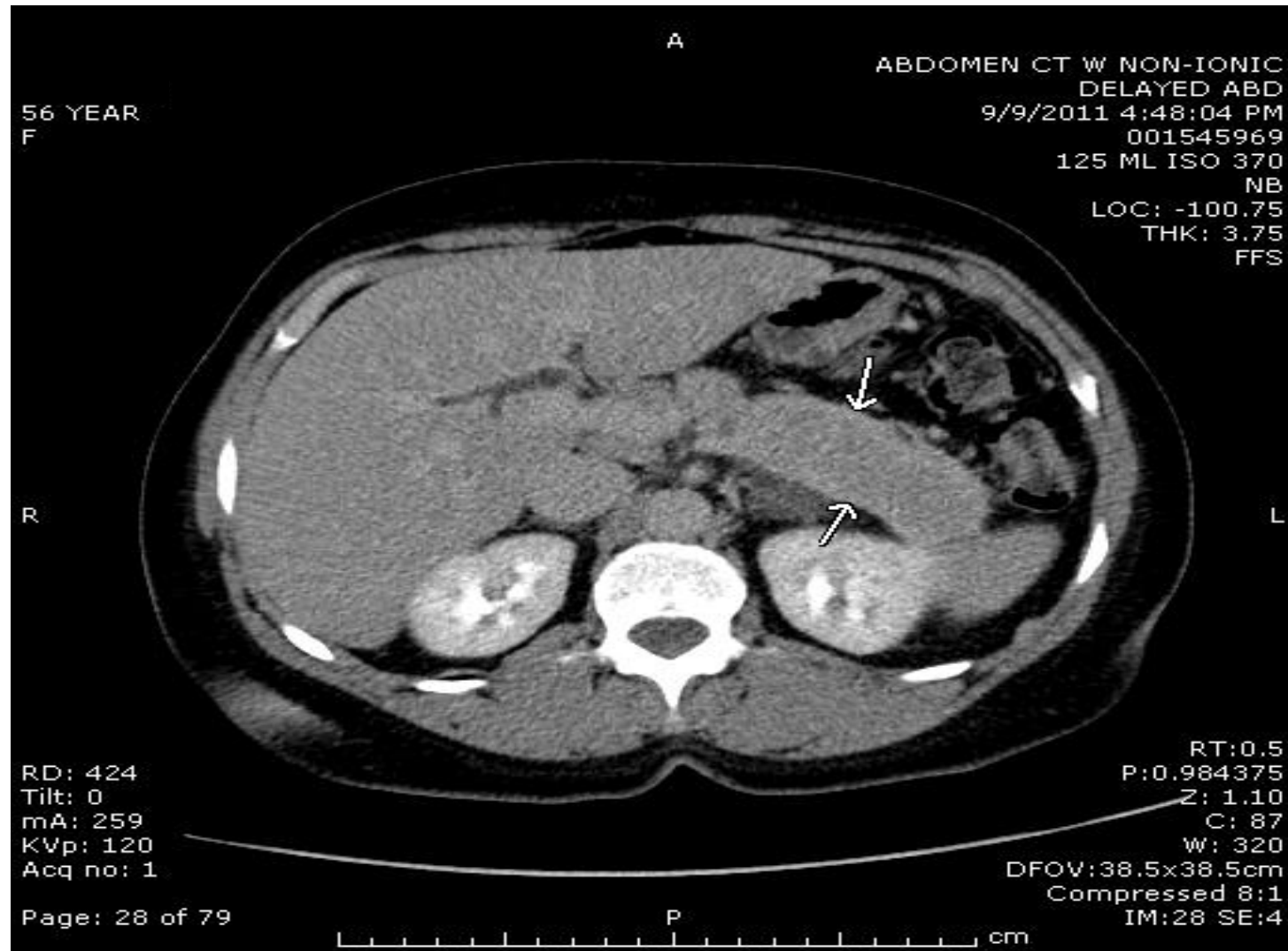
CT – bulbous panc head – no mass



CT – pancreas diffusely thickened with decreased normal lobulations. Hypodense capsule



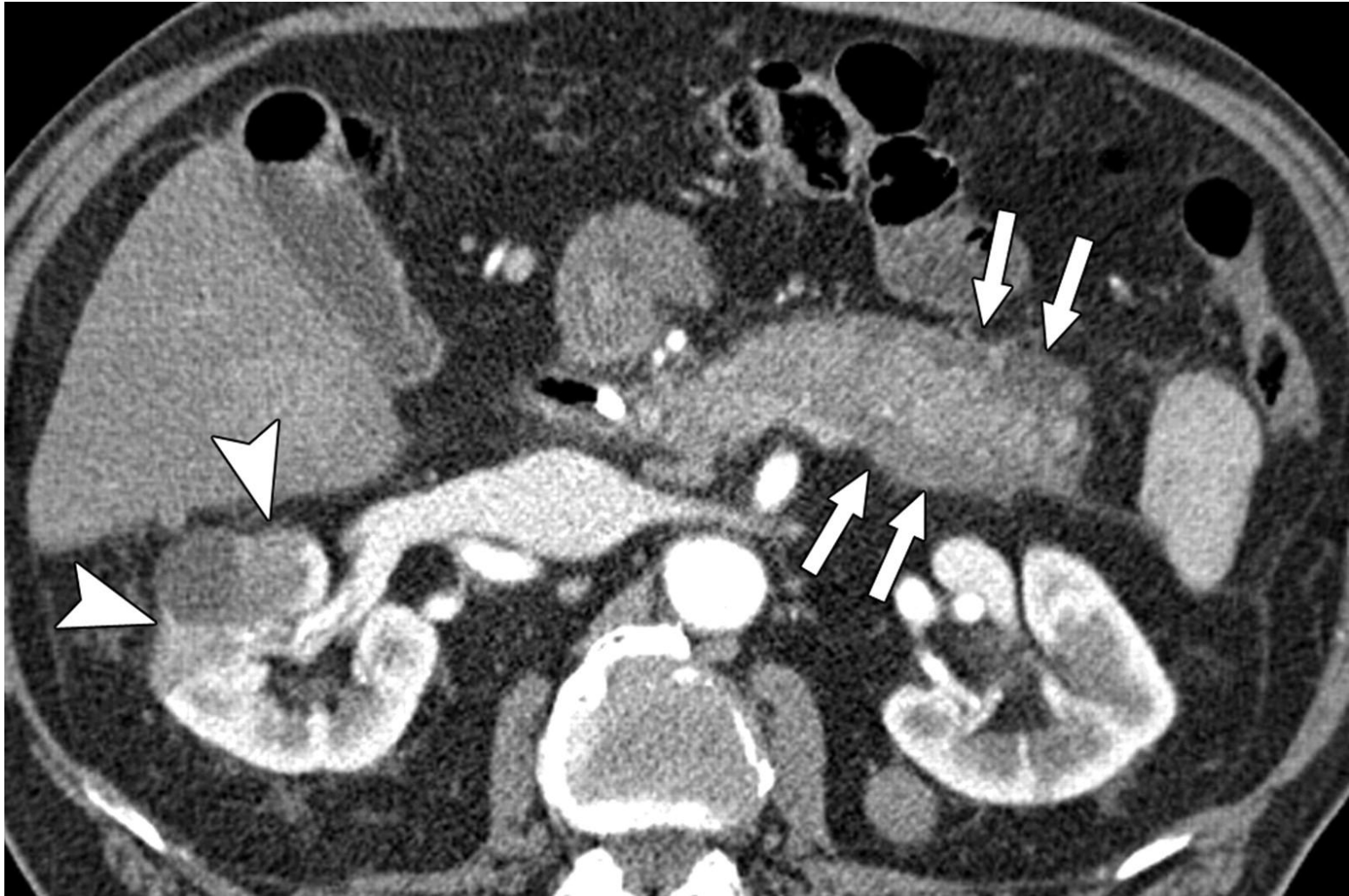Delayed CT- subtle delayed enhancement of “capsule”



Dual-Phase CT of Autoimmune Pancreatitis: A Multireader Study

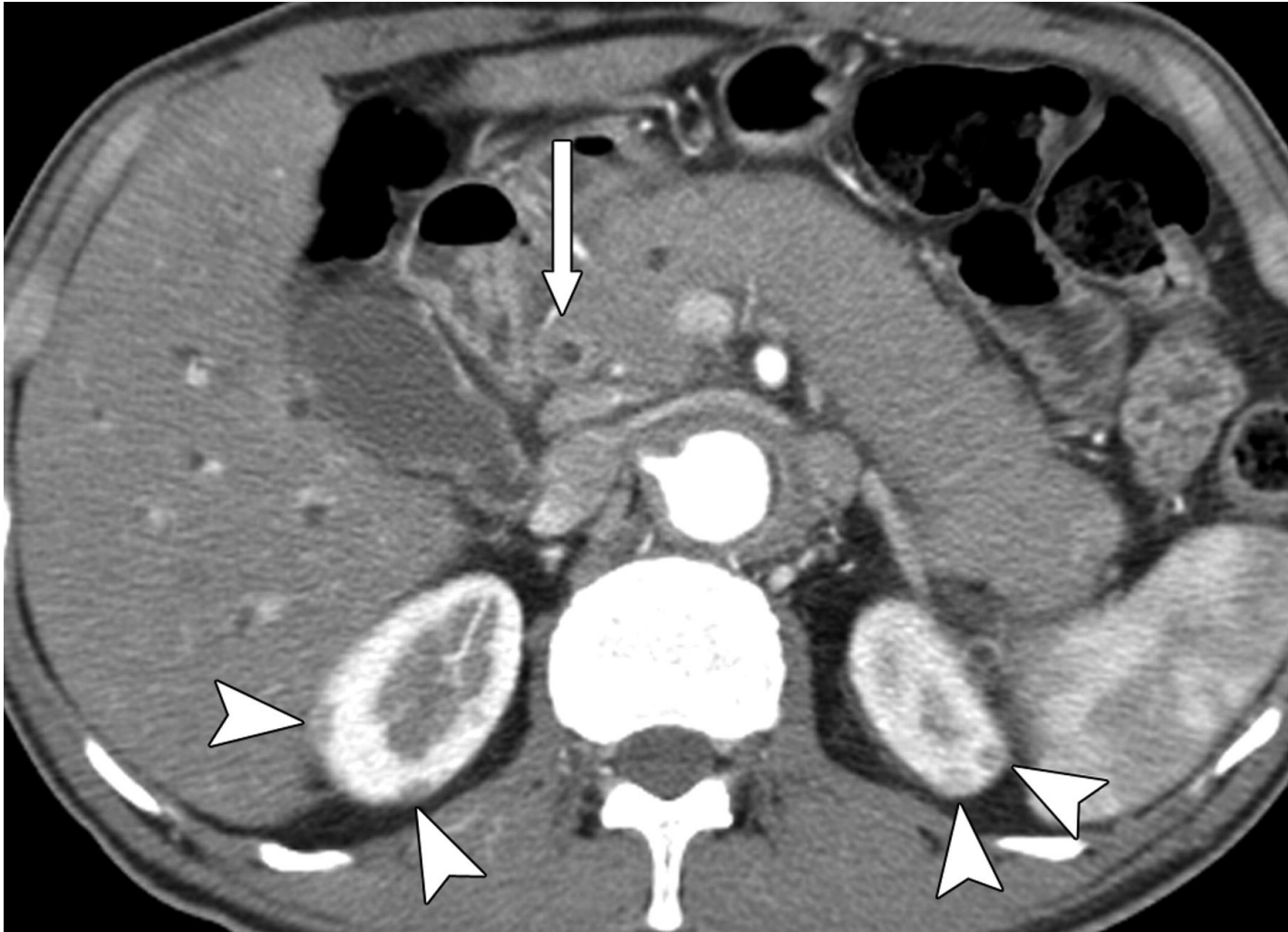
- The characteristic CT appearance of autoimmune pancreatitis has been described as diffuse enlargement of the pancreas with a capsule-like rim [[5](#)–[7](#)].
- *AJR February 2008 vol. 190 no. 2 280-286*

—85-year-old man with autoimmune pancreatitis.



Takahashi N et al. AJR 2008;190:280-286

—74-year-old man with autoimmune pancreatitis.



Takahashi N et al. AJR 2008;190:280-286